



## RHINO-MAXILLARY MUCORMYCOSIS IN COVID 19-DIABETIC PATIENTS WITH EARLY ORAL MANIFESTATIONS: A RETROSPECTIVE STUDY

Srerama Janardhana Rao<sup>1</sup>, Valapula Spandana<sup>2</sup> and Kameswara Rao A<sup>3</sup>

<sup>1,3</sup>Department of Dental Surgery, Andhra Medical College, Visakhapatnam, Andhra Pradesh, India

<sup>2</sup>Department of Periodontics, GITAM Dental College and Hospital, Visakhapatnam, Andhra Pradesh, India

### ARTICLE INFO

#### Article History:

Received 06<sup>th</sup> April, 2022

Received in revised form 14<sup>th</sup>

May, 2022

Accepted 23<sup>rd</sup> June, 2022

Published online 28<sup>th</sup> July, 2022

#### Key words:

Mucormycosis, COVID 19, fungal infection, immunocompromised patients.

### ABSTRACT

The current COVID-19 pandemic has created yet another healthcare issue, with the emergence of a fungal disease that has resulted in a higher fatality rate. COVID-19 patients are predisposed to fungal infections such as mucormycosis, which has been reported in patients who are currently battling and those who have recently recovered, particularly those who are medically compromised. There has been a recent increase in the incidence of rhino--maxillary mucormycosis, which has now become an emerging problem. We report the cases of rhino-maxillary mucormycosis presenting with early oral manifestations to help in early diagnosis and to render early treatment.

**Methods:** We retrospectively investigated fourteen cases of rhino-maxillary mucormycosis presenting initially with oral findings in post-COVID-19 diabetic patients who reported to the Department of Dental surgery, Andhra Medical College, Visakhapatnam, India.

**Statistical analysis:** The data were analysed for age distribution, gender variation, presence of particular clinical signs and symptoms, correlation of clinical and histopathological and radiological findings. Using statistical software SPSS V2, Student t- test and chi-square test was applied to data. P-value equal to or less than 0.05 is considered statistically significant (P<0.05).

**Results:** There was a statistically (P<0.05) significant gender variation, males showed marked predominance(79%), prominent age distribution observed in middle age (40-60 y) when compared to younger and older age group, and significant correlation between clinical, histopathological and radiological findings were observed.

**Conclusions:** Rhino-maxillary mucormycosis is a fatal, emerging fungal infection in COVID- 19 diabetic patients requiring multidisciplinary surgical and medical management. It is observed that early oral manifestations are present in these patients, early detection of these cases through, thorough examination and proper interpretation of clinical and other investigatory findings may prevent the further worsening of infection, helps to save the patient's life and to make the better prognosis of this deadly disease.

Copyright © 2022 *Srerama Janardhana Rao et al.* This is an open access article distributed under the Creative Commons Attribution License, which permits unrestricted use, distribution, and reproduction in any medium, provided the original work is properly cited.

### INTRODUCTION

Mucormycosis is the second most common fungal infection after aspergillus infection. It can progress rapidly into severe infection in immunologically or metabolically compromised patients.<sup>[1,2]</sup> The co-morbidities include trauma, poorly controlled diabetes, inappropriate corticosteroid usage, extended neutropenia, hemopoietic malignancies, hematopoietic stem cell transplant, organ transplant, and prolonged stays in the critical care unit all contribute to the increase of mucormycosis in COVID-19 patients.<sup>[3]</sup> The Rhino-maxillary mucormycosis presentation in covid 19 diabetic patients is frequently observed, diagnosis is often made late and by the time destruction of vital parts may happen, to avoid that early detection of mucormycosis is crucial in some cases. The oral manifestations of rhino-maxillary mucormycosis in COVID-19 individuals include variable degrees of mucosal

colouring, swelling, ulcerations, superficial necrotic regions in the palate, buccal mucosa, sinus tract opening into the oral cavity, bone exposure, and necrosis with dark eschar formation. Swelling on the buccal mucosa, palate, sinus tract openings into buccal or palatal mucosa, buccal and palatal ulcers may be the initial symptom prompting the patient to the dentist, who may be the first doctor to identify an infection and diagnose rhino-maxillary mucormycosis.<sup>[4]</sup>

A non-specific swelling or ulcer of the buccal mucosa and palate could be a presenting sign of mucormycosis, and a dental practitioner must be aware of the disease's early signs and symptoms, especially when screening high-risk patients.<sup>[5]</sup> Early detection of mucormycosis is crucial because treatment should begin as soon as possible to decrease mortality.

In this study, we retrospectively analysed fourteen cases of rhino-maxillary mucormycosis with early oral symptoms in

\*Corresponding author: **Srerama Janardhana Rao**

Department of Dental Surgery, Andhra Medical College, Visakhapatnam, Andhra Pradesh, India

COVID 19 diabetic individuals discussed clinical features, results of laboratory investigations, radiological examinations and treatment outcomes of each case.

## METHODS

Total fourteen cases of rhino-maxillary mucormycosis patients with early oral symptoms initially presenting to the Department of Dental surgery, Andhra Medical College, Visakhapatnam, India, were retrospectively investigated. Written informed consents were taken from the fourteen patients for publication of this research article and any images. Institutional Ethical Committee approval was taken from the Andhra Medical College, Visakhapatnam. For fourteen cases name, age, sex, detailed history (diabetic and COVID 19), extra-oral and intraoral clinical signs and symptoms including extraoral swelling of the cheek (Figure 1), lower and upper eyelid, intraoral swelling of the palate (Figure 3), swelling in the buccal mucosa, sinus draining into oral mucosa (Figure 4), mobility of the teeth, exposed necrotic alveolar bone (Figure 2), laboratory investigations results like haematological, histopathological and radiological examinations details were recorded. The diagnosis of rhino-maxillary mucormycosis was done based on histopathological examination of biopsy samples and CT scan (Figure 5,6) confirmation of the involvement of nasal and maxillary components in every patient.<sup>[6]</sup>

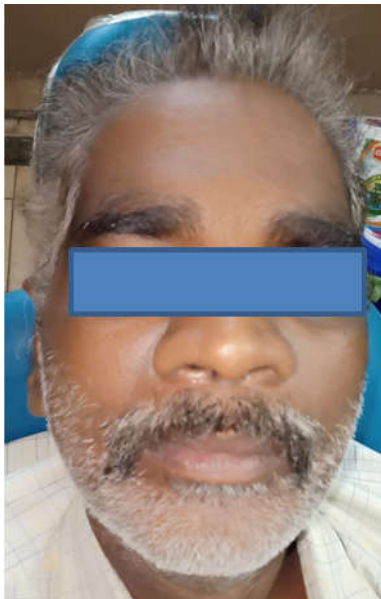

Figure 1 Extra oral swelling of the left cheek.

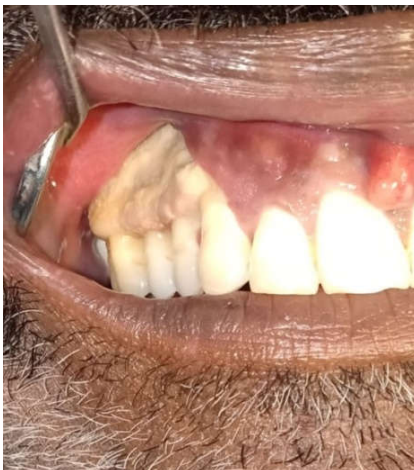

Figure 2 Denudation of alveolar bone.

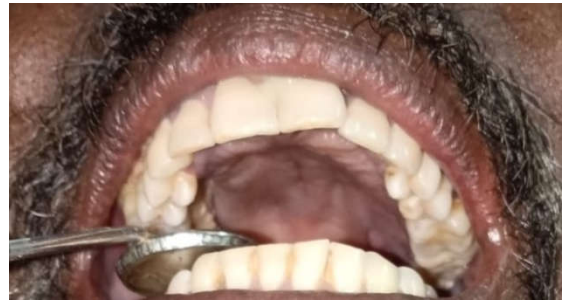

Figure 3 Swelling of the palate.

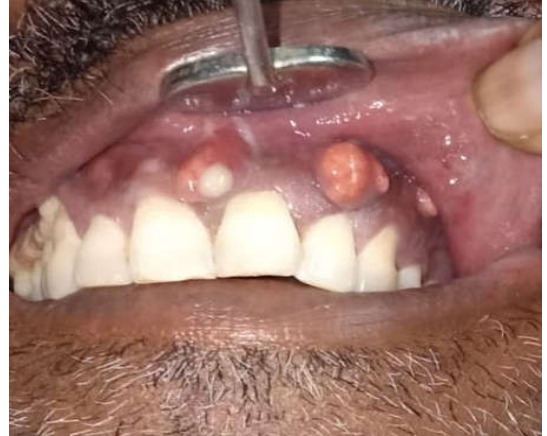

Figure 4 Sinus opening with pus drainage.

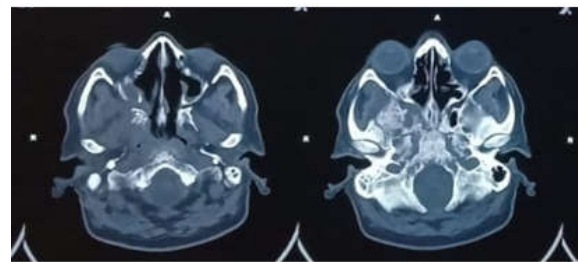


Figure 5 CT images showing irregular erosion of walls of the right and left maxillary sinus.

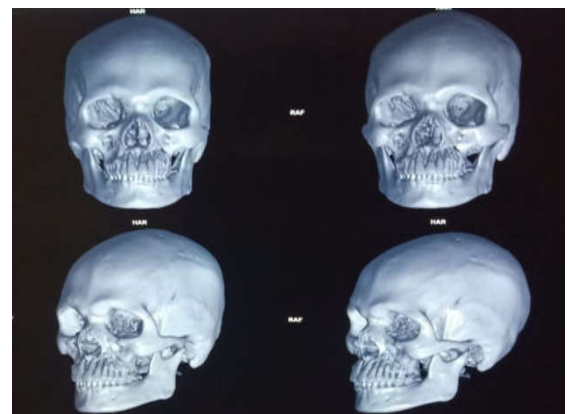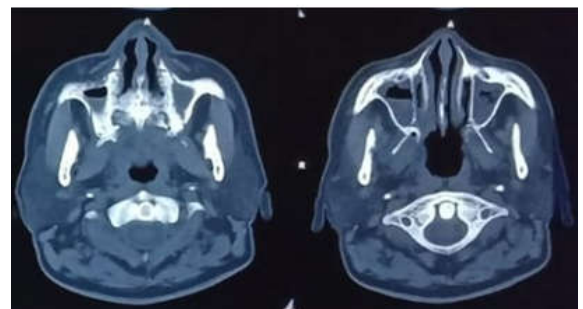


Figure 6 3D CT images showing irregular erosion of walls of the right and left maxillary sinus.

**Statistical Analysis**

The data was analysed for age distribution, gender variation, presence of particular clinical signs and symptoms, correlation of clinical and histopathological and radiological findings using statistical software SPSS V22, and the chi-square test were applied to data. P value equal to or less than 0.05 is considered statistically significant (P<0.05).

**RESULTS**

In this study post-COVID, 19 diabetic individuals presenting with oral manifestations were mainly presented in the age group ranging between 40yrs-60yrs(8 cases,62%) followed by age group of above 60yrs( 3 cases,23%) (Chart 1). However, younger individuals in the age group of 20yrs-40yrs were less(2 cases,15%).

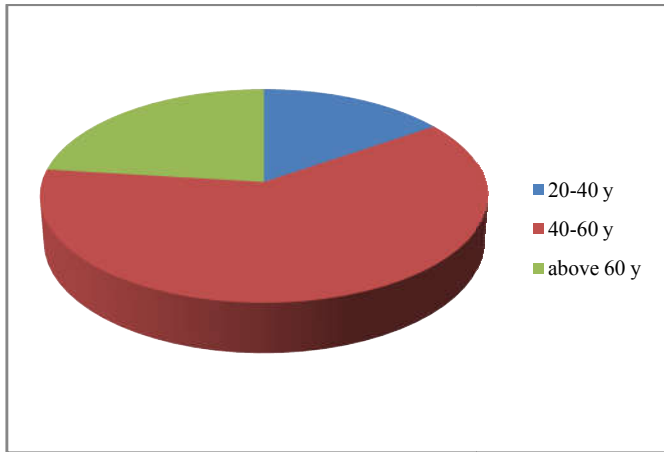


Chart 1 Age distribution of post COVID- 19 diabetic patients.

Gender distribution when compared to females(3 cases, 21%), males(11 cases,79%) showed increased presence of mucormycosis (Chart 2).

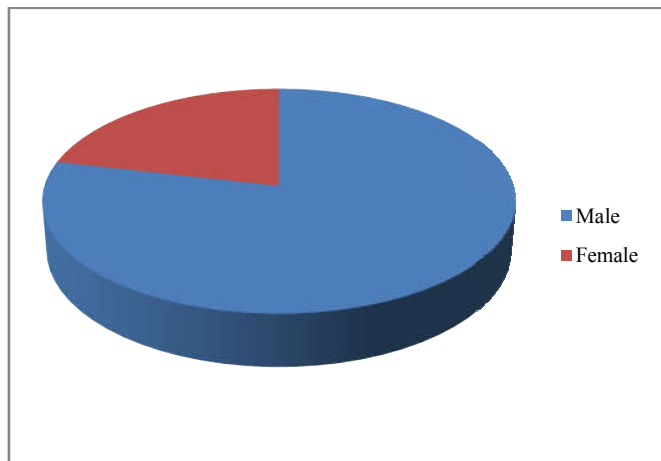


Chart 2 Gender distribution in post COVID- 19 diabetic patients.

Clinical signs and symptoms such as pain in maxilla or teeth(13 cases,93%), nasal stuffiness, swelling of buccal mucosa, sinus opening with pus drainage and facial swelling(12 cases,86%) were most commonly present in most of the individuals. Fever (10 cases,71%), palatal swelling, headache (9 cases,64%), mobility of teeth (8 cases,57%)were the next common symptoms noted in the patients in this study. However, denudation of alveolar bone (3 cases,21%) was reported in a few cases that presented relatively late after initial symptoms have appeared. Patients also presented with a history of recent tooth extraction(2cases,14%) due to pain and

mobility after which the symptoms have worsened which included increased pain and pus drainage into the buccal mucosa(Table- 1).

**Table 1** Descriptive statistics of obtained data.

| S No                        | Parameter                       | Number of cases | Percentage |
|-----------------------------|---------------------------------|-----------------|------------|
| Age                         | 20-40 Y                         | 2               | 15%        |
|                             | 40-60 Y                         | 8               | 62%        |
|                             | Above 60 Y                      | 3               | 23%        |
| Gender                      | Male                            | 11              | 79%        |
|                             | Female                          | 3               | 21%        |
| Clinical Signs and Symptoms | Facial swelling                 | 12              | 86%        |
|                             | Pain In Maxilla or Teeth        | 13              | 93%        |
|                             | Palatal swelling                | 10              | 71%        |
|                             | Swelling of Buccal mucosa       | 13              | 93%        |
|                             | Sinus opening with Pus drainage | 13              | 93%        |
|                             | Mobility of teeth               | 8               | 57%        |
|                             | Denudation of Alveolar bone     | 3               | 21%        |
|                             | Fever                           | 10              | 71%        |
|                             | Headache                        | 9               | 64%        |
|                             | Nasal stuffiness                | 13              | 93%        |
|                             | Trauma(Dental Extraction)       | 2               | 14%        |

There was a statistically (P<0.05) significant gender variation, prominent age distribution, and significant correlation between clinical, histopathological and radiological findings was observed (Chart 3).

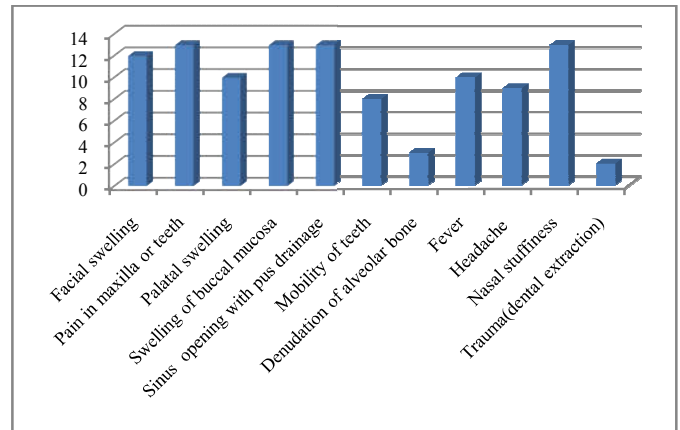


Chart 3 Clinical signs and symptoms in rhino-maxillary mucormycosis cases.

**DISCUSSION**

The global prevalence of diabetes was estimated to be 9.3% in the year 2019 affecting 463 million people worldwide and is on the rise and estimated to affect 573 million people by the year 2030.[7] According to studies done by Kontayannis D P and Rammaert *et al.*, there is 8 fold increased risk of mucormycosis in diabetic individuals. Diabetes is considered an independent risk factor for mucormycosis in uncontrolled diabetics and diabetic ketoacidosis are frequently associated with mucormycosis.[8,9]

The rising trend of mucormycosis in uncontrolled diabetes mellitus has increased fatality range of 30%- 57%. There is an increased prevalence of mucormycosis during this COVID 19 pandemic. Studies by Skiada A reported 80 times higher prevalence of mucormycosis in India, which was attributed to increased prevalence of diabetes prevalence in India and also due to increased corticosteroid use for the treatment of SARS Co V 2 virus.[7]

Rhino-orbito-cerebral mucormycosis is the most common form of mucormycosis that has been observed in diabetic



individuals. It presents with different stages of disease primarily involving the paranasal sinuses after which in the second stage it shows orbital invasion and finally leads to cerebral invasion. There is an increased mortality rate of greater than 80% with intracranial involvement. Limiting its spread helps in decreasing the mortality rate. The fungi show rapid dissemination and delay in diagnosis and treatment could be fatal.<sup>[10,11]</sup>

Trauma, poorly controlled diabetes, corticosteroid usage all contribute to the increased risk for mucormycosis in COVID-19 patients. In the present case report, the patient presented with various risk factors such as recent trauma due to extraction of the tooth, previous history of diabetes, and history of being COVID-19 positive which may have contributed to increased risk for Mucormycosis.

The initial symptoms presented by the patient were of dental origin. However, Mucormycosis in its primary stage mainly infects the paranasal sinus followed by orbital invasion in its secondary stage. Infection of the paranasal sinus can initially present as swelling, and pain in the maxillary tooth, and palate. Thereby, dentists should have a thorough knowledge of oral manifestations of Mucormycosis to help in early diagnosis and prevent its cerebral spread by rendering early treatment.<sup>[12]</sup> A thorough history and careful oral examination help in early diagnosis to render early treatment which substantially decreases the mortality rate.

## CONCLUSION

Rhino-maxillary mucormycosis is a life threatening fungal infection in COVID-19 diabetic patients requiring multidisciplinary surgical and medical management. It is observed that early oral manifestations are present in these patients, early detection of these cases through, thorough examination and proper interpretation of clinical and other investigatory findings may prevent the further worsening of infection, helps to save the patient's life and to make the better prognosis of this life threatening disease.

### List of abbreviations

None.

### Ethical consideration

Institutional Ethical Committee approval was taken from the Andhra Medical College, Visakhapatnam, Andhra Pradesh, India.

### Consent for publication

Written informed consent for publication of participants' clinical images was obtained from all patients.

### Availability of data and materials

The datasets used and/or analysed during the current study are available from the corresponding author on reasonable request.

### Competing interests

No competing interests.

### Funding

None

### Acknowledgements

My sincere thanks to Dr.V.Varaprasad, Professor, for his academic advice and guidance.

### References

1. Pfaffenbach B, Donhuijsen K, Pahnke J, Bug R, Adamek RJ, Wegener M, *et al.* Systemic fungal infections in hematologic neoplasms. An autopsy study of 1,053 patients] *Med Klin (Munich)*. 1994;89(6):299–304.
2. Denning DW, Stevens DA. Antifungal and surgical treatment of invasive aspergillosis: review of 2,121 published cases. *Rev Infect Dis*. 1990;12(6): 1147–201.
3. Walsh TJ, Groll AH. Emerging fungal pathogens: evolving challenges to immunocompromised patients for the twenty-first century. *Transpl Infect Dis*. 1999;1(4):247–61.
4. Amorim Dos Santos J, Normando AGC, Carvalho da Silva RL, Acevedo AC, De Luca Canto G, Sugaya N, *et al.* Oral Manifestations in Patients with COVID-19: A Living Systematic Review. *J Dent Res*. 2021 Feb;100(2):141-154.
5. Sanath AK, Nayak MT, Jd S, Malik SD, Aithal S. Mucormycosis occurring in an immunocompetent patient: a case report and review of literature. *CeskPatol*. 2020;56(4):223-6.
6. Jiang N, Zhao G, Yang S, Lin J, Hu L, Che C, Wang Q, Xu Q. A retrospective analysis of eleven cases of invasive rhino-orbito-cerebral mucormycosis presented with orbital apex syndrome initially. *BMC Ophthalmol*. 2016 Jan 12;16:10.
7. Skiada A, Pavleas I, Drogari-Apiranthitou M. Epidemiology and Diagnosis of Mucormycosis: An Update. *J Fungi*. 2020 Nov 2;6(4):265.
8. Hamilos G, Samonis G, Kontoyiannis DP. Pulmonary mucormycosis. *Semin Respir Crit Care Med*. 2011 Dec;32(6):693-702.
9. Rammaert B, Lanternier F, Poirée S, Kania R, Lortholary O. Diabetes and mucormycosis: a complex interplay. *Diabetes Metab*. 2012 Jun;38(3):193-204.
10. Patel A, Kaur H, Xess I, Michael JS, Savio J, Rudramurthy S, *et al.* A multicentre observational study on the epidemiology, risk factors, management and outcomes of mucormycosis in India. *Clin Microbiol Infect*. 2020 Jul;26(7):944.e9-944.e15.
11. Bhansali A, Bhadada S, Sharma A, Suresh V, Gupta A, Singh P, Chakarbarti A, Dash RJ. Presentation and outcome of rhino-orbital-cerebral mucormycosis in patients with diabetes. *Postgrad Med J*. 2004 Nov;80(949):670-4.
12. Raut A, Huy NT. Rising incidence of mucormycosis in patients with COVID-19: another challenge for India amidst the second wave? *Lancet Respir Med*. 2021 Aug;9(8):77.

### How to cite this article:

Srerama Janardhana Rao *et al* (2022) 'Rhino-Maxillary Mucormycosis in Covid 19-Diabetic Patients with Early Oral Manifestations: A Retrospective Study', *International Journal of Current Medical and Pharmaceutical Research*, 08(07), pp 317-320.