

## ACUTE APPENDICITIS IN PREGNANCY: 33 CASES

Alaarabiou A, Rabbani K, Louzi A and Finech B

Department of Visceral Surgery, University Hospital Centre Mohammed VI, Marrakech, Morocco

### ARTICLE INFO

#### Article History:

Received 6<sup>th</sup> August, 2019

Received in revised form 15<sup>th</sup>  
September, 2019

Accepted 12<sup>th</sup> September, 2019

Published online 28<sup>th</sup> November, 2019

#### Key words:

Appendicitis – Pregnancy – Diagnosis  
– Treatment

### ABSTRACT

Acute appendicitis is the most common nonobstetric surgical emergency during pregnancy. Its occurrence during pregnancy exposes it to additional diagnostic difficulties and transforms the current pregnancy into a pregnancy at risk. Our series includes 33 cases of acute appendicitis and pregnancy. The objective of the study is to describe the characteristics of acute appendicitis in pregnant women. In terms of epidemiology most studies find a predominance of primary patients with acute appendicitis, in our study it was more the multipares. The age of onset of acute appendicitis is between 18 and 44 years of age so there is a larger proportion of onset in the second trimester of pregnancy. Despite the many possible tables, the most constant sign of examination at any stage of pregnancy remains the pain caused at the level of the right iliac fossa and this despite the migration of the appendix. Biology is only an additional diagnostic tool that does not alone affirm or deny the diagnosis. Ultrasound may specify, correct or support a suspected diagnosis. The scanner is not without danger, but its high performance may, in case of questionable clinical presentation, be of valuable help. During the operation any hypoxia, hypotension, hypertension, acidosis, hypo or hyperventilation should be avoided. Coelioscopy adds other risks related to pneumoperiton. Coelioscopic surgery during pregnancy and in particular appendectomy has many advantages over laparotomy and seems to be safe for more and more advanced stages of pregnancy. The use of tocolytic agents must be case-specific, its indications are not consensual and their effectiveness in prophylactic measurement is not demonstrated. In our context, there is no place for coelioscopic surgery for appendectomy during pregnancy and laparotomy takes its place. Appendicitis and pregnancy are a high-risk maternal-fetal association whose prognosis depends on the early diagnosis and therapeutic management.

Copyright © 2019 Alaarabiou A, Rabbani K, Louzi A and Finech B. This is an open access article distributed under the Creative Commons Attribution License, which permits unrestricted use, distribution, and reproduction in any medium, provided the original work is properly cited.

### INTRODUCTION

Acute appendicitis is the most common nonobstetric surgical emergency during pregnancy. Its occurrence during pregnancy exposes it to additional diagnostic difficulties and transforms the current pregnancy into a pregnancy at risk. The aim of this work was to describe the characteristic of acute appendicitis in the pregnant woman in term of clinical, biological, radiological diagnosis, treatment and prognosis.

### METHODS

It is a descriptive retrospective study of 33 cases of pregnant women operated on for acute appendicitis at any developmental stage, collected at the visceral surgery department of university hospital Mohammed VI in Marrakech (Morocco). over a period of 5 years from January 2012 to December 2016.

### RESULTS

During the study period, 3751 women received an appendectomy at the department of visceral surgery. Acute

appendicitis occurred in pregnant women once for 113 appendicitis, or 0.8%. The average age of our patients was 24.6 years, with extremes ranging from 18 to 44 years. The average gesture in our series was 3.2 while the average parity was 2.3. There were 18 multiparous and 15 primiparas. Gestational age was in the first trimester in 36.36% of cases (n=12) and in the second trimester in 42.42% (n=14) and in the third trimester in 24.24% (n=8).

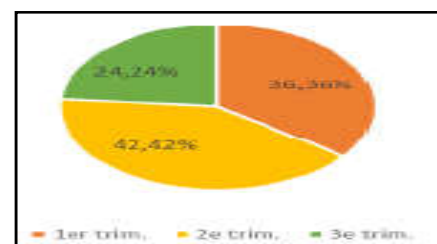


Chart 1 Distribution of gestational age in our patients

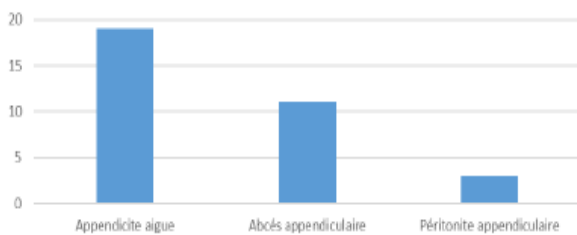
Abdominal pain was the main symptom and the first symptom to appear in all patients. It was mainly located in the right iliac fossa. Vomiting was an associated symptom in 3 cases, nausea

\*Corresponding author: Alaarabiou A,

Department of Visceral Surgery, University Hospital Centre Mohammed VI, Marrakech, Morocco

in 5 cases, fever in 21 cases, only one patient had urinary burns and another had uterine contractions but no metrorrhagia or cervical abnormalities. Abdominal defence was present in 3 patients (9.09%), a defence or sensitivity of the right iliac fossa in 22 cases (66.66%) and a defence or sensitivity of the right flank in 6 cases (18.18%) and a mass of the right iliac fossa in 2 cases (6.06%).

Biologically, the leukocyte count was performed in all of our patients with hyperleukocytosis ( $>10,000$ ) in 9 of them (27.27%). CRP was performed in 23 patients (69.69%), and was elevated ( $>5$ ) in all patients. Urine cytobacteriological examination was performed 16 times (48.48%), with no germs. Abdominal and obstetric ultrasound were performed in all patients and was suggestive of acute appendicitis in 19 patients (57.57%) and appendicular abscesses in 11 patients (33.33%) while the appearance of appendicular peritonitis was noted in 3 patients (9.09%) (Chart 2). The fetus was alive in all patients and there was no associated pathology.



**Chart 2** Abdominal ultrasound results of patients in our series (numbers)

All patients received pain medication combined with antibiotic therapy. Tocolysis was initiated at induction of anesthesia, continued in preoperative and postoperative mode for 24 hours based on progesterone in the first trimester, and nifedipine in the second and third trimesters.

Our patients were operated on by laparotomy with Mac Burney incision in 30 cases (90.90%), and a median incision straddling the umbilicus in 3 cases (9.09%). The appendix was in the lateral-internal caecal position in 78.8% of the cases and retro caecal in 21.2% of the cases. Surgery consisted of an appendectomy in 100% of cases, with peritoneal flushing and drainage in the case of abscesses or peritonitis in 14 cases (42.42%). The anatomopathological study was in favour of acute appendicitis with no signs of malignancy in all patients in our series, it also revealed appendicular mucocele in 1 patient (3.03%), which was re-performed for hemaicolectomy after delivery.

The average hospital postoperative stay was 4.7 days. Maternal mortality was nil. Maternal morbidity was represented by 4 cases of parietal suppuration (12.12%). One case of abortion was reported in a patient pregnant and operated for peritonitis. Fetal death was observed in a pregnant woman in the 3rd trimester (3.03%).

## DISCUSSION

Surgical indications for nonobstetric pathologies concern 0.2 to 2% of pregnancies. The most frequent etiologies are acute appendicitis, acute cholecystitis, surgery of the annexes (1). For some, the high level of progesterone during pregnancy would promote acute appendicitis by decreasing intestinal mobility (4). Prevalence of acute appendicitis during pregnancy varies between studies, ranging from 1/1440 to 1/1783 pregnancies (1,2,3).

Most of the studies are now dominated by primary patients with acute appendicitis (1, 5). This is due to the average age of onset of acute appendicitis, which, as in the general population, is between 24 and 30 years of age, whereas many women are still only primitive. These studies show a higher proportion of the second trimester of pregnancy: 48-51% (1, 3). This data is affected by several means: the lower prevalence in the first trimester of pregnancy is explained by the fact that most studies are carried out by obstetricians and thus exclude women who have acute appendicitis at the beginning of pregnancy and who are managed in digestive surgery. Similarly, acute appendicitis at the end of pregnancy often results in fetal extraction before appendicectomy. Series that include acute appendicitis during pregnancy exclude these cases (3). The results found in our series coincide with these data for the trimester of occurrence, but we found a slight predominance among the multiparous. The clinical diagnosis of acute appendicitis during pregnancy presents varying difficulties depending on gestational age. In the first trimester, the semiology of appendicitis is no different from that observed in the non-pregnant woman. Abdominal pain is the most common sign. It has been found in all patients in our series, 96% of the 720 cases studied by Mahmoodian and al (1), with different opinions as to its location. The frequency of spontaneous localization of pain in the right iliac fossa varies significantly among authors (1,3,7). Other more or less frequent locations of pain: epigastric, periumbilical, right hypochondrium (32% (88), 20% (1)). This pain may lead to discussion of a threat of early abortion or urinary tract infection, hence the interest of the obstetric examination and urine cytobacteriological examination. In our study, these two tests were normal outside of uterine contractions in a patient (3.03%). The other functional signs of appendicitis (nausea, vomiting, constipation) are common during pregnancy at this gestational age, which takes away any diagnostic interest. In our study 3 patients had vomiting (9.09%) and 5 patients had nausea. During the last two trimesters of pregnancy, the diagnosis of appendicitis becomes more difficult because of a change in the ratio of the appendix and the uterus. The appendix is pushed up and out and reaches the costal rim on the 8th. Pain is located in the right flank or hypochondrium. It may be accompanied by uterine contractions suggesting a threat of late abortion or premature delivery. The blood count is difficult to interpret because of the physiological hyperleucocytosis of pregnancy (9), while the CRP may be normal (10). These two tests are therefore of little interest in the diagnosis of appendicitis during pregnancy.

Abdominal-pelvic ultrasound confirms diagnosis when it visualizes an incompressible appendix greater than 7 mm in diameter, aperitif with a parietal thickness of more than 3 mm and sometimes a presence of liquid in the appendicular light (9,10). Performed by a trained operator, ultrasound has a sensitivity of 100 % and a specificity of 96 % at this gestational age [11]. Its interest is also to eliminate an associated annexial or obstetrical pathology, to document the pregnancy by specifying gestational age and fetal vitality. In our patients, ultrasound was an excellent contribution, confirming the diagnosis of appendicitis in all cases. We therefore recommend ultrasound because of the availability of machines, the performance of the examination in gynecological pathology and the absence of irradiation. Computed tomography remains the gold standard for imaging in non-pregnant patients, but to be avoided in pregnant women

for fear of increasing the risk of developing childhood cancers, and the possibility of interfering with organogenesis, especially between the 2nd and 15th of gestational age. This has led to the increased use of magnetic resonance imaging for the diagnosis of appendicitis during pregnancy, especially when ultrasound results are inconclusive. We don't have experience with coelioscopy in the diagnosis of acute appendicitis. It allows a diagnostic approach in that it visualizes the appendix and specifies its location (9,12). It avoids white laparotomy and can diagnose other causes of abdominal pain such as extra-uterine pregnancy (9,13). It is contraindicated beyond the 20th week due to the risk of uterine wound and fetal risk related to abdominal hyperpressure which would lead to a reduction in uterine blood flow/placental (12). However, some authors believe that coelioscopy is possible in the 2nd trimester and even beyond by exploiting the free space between the previously identified uterine floor and the xiphoid appendix (12,14).

Complications of acute appendicitis during pregnancy are the same as outside pregnancy (15). In the first trimester, all complications of appendicitis can be seen. On this date, the still pelvic uterus does not suppress neighboring organs that can form adhesions around the appendicular focal point and isolate it from the peritoneal cavity making an appendicular plastron. The development of the appendicular crisis may also be towards diffuse acute peritonitis. In the last two trimesters, there is nothing to prevent the spread of appendicular infection. In fact, uterine contractions hinder the formation of adhesions and the partitioning of the infection; high steroid levels decrease inflammatory response and increased pelvic vascularization facilitates the spread of infection (16,17,18). All of these reasons explain the more rapid evolution towards peritonitis in the third trimester.

According to the latest recommendations (19), antibiotic prophylaxis is recommended. It reduces the risk of parietal infection and deep abscess. She has to start preoperative, then continue per- and postoperative. The duration of administration and the type of antibiotic still need to be assessed. Regarding curative antibiotic therapy, most authors agree that it should only be indicated in the case of complicated acute appendicitis (perforated, gangrenes, abscess, with or without peritonitis). They recommend the use of a 3rd or 2nd generation cephalosporin associated with metronidazole or ampicillin associated with metronidazole (10, 12). It shall be maintained and adapted to the antibiogram taken from the collection of the peritoneal fluid up to a period greater than 48 hours. For uncomplicated forms, it can be stopped in immediate postoperative mode depending on the clinical course (19).

If the indication of tocolysis is not discussed before a table of threat of premature delivery, prophylactic, pre and/or postoperative tocolysis is controversial: desire, on the one hand to avoid at all costs a threat of premature delivery and on the other hand, fear of adverse effects. For many authors, it is indicated only for curative purposes (1, 10). Some recommend systematic preoperative prophylaxis (10). Others recommend systematic postoperative tocolysis before fetal viability although its effectiveness is not demonstrated (20, 21). For many, this is a matter of personal conviction, given the lack of conclusive studies for fetal benefit (21, 2). In our context, prophylactic tocolysis for 48 hours is systematic. Calcium

blockers are used as first-line inhibitors. If they fail, they go to beta-optics.

All patients were operated on by laparotomy. The technique for the treatment of acute appendicitis and appendicular peritonitis doesn't present any particularity in pregnant women [15]. The Pathway first depends on the stage of pregnancy, clinical presentation and whether or not a diagnostic doubt or associated pathology is present. At the beginning of pregnancy: the classic right lateral first path with incision at the Mac Burney point is the most commonly practiced (1). In the event of a diagnostic doubt, a paramedical pathway will be possible. In the last two trimesters: the incision must be higher, located in the right flank. These high incisions allow to resolve the operating difficulties related to the migrations of the cecum in the 2nd and 3rd trimesters. For some authors, the cæco-appendicular region would be better exposed by a mid-umbilical incision in the 2nd trimester and a Jalaguier incision in the 3rd trimester. However, in the diffuse appendicular peritonites, the median incision straddling the umbilicus allows for a quick start and a thorough exploration of the abdominal cavity as we did in the 3 observed cases. Coelioscopy reduces uterine manipulation in relation to the need to explore and in appendicular peritonites, preserves the abdominal parietal capital and allows a better abdominal toilet. The appendectomy is performed either intraperitoneally or transparietal if the appendicitis is removed by a slightly enlarged suprapubic incision (10). Coelioscopy, which is contraindicated in case of scar abdomen due to the risk of adhesions (10), would reduce the length of hospitalization and doses of anaesthetic products without increasing morbidity.

The maternal-fetal prognosis is a function of the severity of the condition and the delay in treatment (10,16). No maternal deaths were noted in our work as in other series (1,3, 9). This is due, according to Tshibangu et al. (16), to the early diagnosis and treatment. Fetal death observed in a case of peritonitis with appendicular perforation diagnosed and treated 4 days after admission. Fetal mortality is more than 35% in appendicular peritonitis (10,20) and ranges from 1% to 8% in women with uncomplicated acute appendicitis (19, 20). We noted a premature delivery that was not related to the appendicular condition. Prematurity and spontaneous delivery are the main fetal risks. The rate of threat of premature delivery fluctuates between 6.4% (1) and 22% (7), the rate of prematurity from 0 to 20% according to the authors (4.8% (1)). This risk would be higher in the 3rd trimester.

## CONCLUSION

Acute appendicitis in pregnant women is a rare and relatively difficult diagnosis. In the first trimester, diagnosis is easy, treatment simple and prognosis generally good. In the last 2 trimesters, diagnostic difficulties are responsible for severe forms and aggressive surgical treatment. Pelvic ultrasound and urine cyto-bacteriological examination should be systematic for abdominal pain in pregnant women. Diagnostic doubt requires surgical exploration. The primary risk factor for maternal-fetal mortality is management time, related to the rate of appendicular perforation. Surgery during pregnancy must be performed according to a codified protocol. Maternal and fetal mortality have been reduced due to advances (antibiotic therapy, surgical techniques, intensive perioperative monitoring).

### Competing interests

The authors declare no competing interests.

### References

1. To WW, Ngai CS, Ma HK. Pregnancies complicated by acute appendicitis, *The Australian and New Zealand Journal of Surgery*, 1995, 65(11): 799-803.
2. Mazze RI, Källén B. Reproductive outcome after anesthesia and operation during pregnancy: A Registry study of 5405 cases, *American Journal of Obstetrics and Gynecology*, 1989, 161(5): 1178-1185.
3. Mazze RI, Källén B. Appendectomy during pregnancy: a Swedish registry study of 778 cases, *Obstetrics & Gynecology*, 1991, 77(6): 835-840.
4. To WW, Ngai CS, Ma HK. Pregnancies complicated by acute appendicitis, *The Australian and New Zealand Journal of Surgery*, 1995, 65(11): 799-803.
5. Nouira M, Jerbi M, Sahraoui W, Mellouli R, Sakhri J, Bouguizane S, Saïdi H, Bibi M, Khaïri H. Appendicite aiguë chez la femme enceinte: à propos de 18 cas, *Revue française de gynécologie et d'obstétrique*, 1999, 94(6): 486-491.
6. To WW, Ngai CS, Ma HK. Pregnancies complicated by acute appendicitis, *The Australian and New Zealand Journal of Surgery*, 1995, 65(11): 799-803.
7. Tamir IL, Bongard FS, Klein SR. Acute appendicitis in the pregnant patient, *The American Journal of Surgery*, 1990, 160(6): 571-576.
8. Nouira M, Jerbi M, Sahraoui W, Mellouli R, Sakhri J, Bouguizane S et al. Appendicite aiguë chez la femme enceinte: à propos de 18 cas. *Rev Fr Gynecol Obstet* 1999; 94: 486-91.
9. Tamirel P, Kessler N, Blayac PM, Lesmik A, Gallix B, Bruel JM. Imagerie de l'appendicite. *Échographie, scanner ou rien du tout. J Radiol* 2002; 83: 1952-60.
10. Lim HK, Bae SH, Seo GS. Diagnosis of acute appendicitis in pregnant women: value of sonography. *AJR* 1992; 159: 539-42.
11. Batallan A, Benifla JC, Panel P, Dorin S, Daraï E, Madelenat P. Chirurgie laparoscopique au deuxième trimestre de la grossesse: indication, technique et retentissement fœtal. À propos de 9 observations et revue de la littérature. *Ann Chir* 1999; 53: 285-90.
12. Marret H, Laffon H, De Calan L, Bourlier LP, Lansac J. Urgences chirurgicales au cours de la grossesse. *Encycl Med Chir, Gynécologie Obstétrique*, 5-049- D10, 2000, 13 p.
13. Barnes SL, Shane MD, Shoemann MB, Bernard AC, Boulanger BR. Laparoscopic appendectomy after 30 weeks pregnancy: report of two cases and description of technique. *Am Surg* 2004; 70: 733-6.
14. Adloff M, Schloegel M. Appendicite. *Encycl Med Chir. Estomac intestin*. 9066 a 10, 10-1989, 10 p.
15. Berthet-Badetti L, Tanti MC, Boimond H. Appendicite aiguë au troisième trimestre de la grossesse. *Rev Fr Gynecol Obstet* 1997; 92: 205-7.
16. Leroy JL. L'appendicite aiguë au cours de la gravidopuerpéralité: les difficultés du diagnostic et du traitement. *Med Chir Dig* 1981; 10: 143-7.
17. Maisonnète F, Dubayle G, Aubard Y, Baudet JH. Appendicite aiguë au cours des deux derniers trimestres de la grossesse. *Rev Fr Gynecol Obstet* 1999; 94: 66-9.
18. Borie F, Philippe C. Appendicite aiguë. EMC (Elsevier Masson SAS, Paris) Gastroentérologie, 2011: 9-066.
19. Hunt MG, Martin JN Jr, Martin RW, Meeks GR, Wiser WL, Morrison JC. Perinatal aspects of abdominal surgery for nonobstetric disease, *American Journal of Perinatology*, 1989, 6(4): 412-7.
20. Hée P, Viktrup L. The diagnosis of appendicitis during pregnancy and maternal and fetal outcome after appendectomy, *International Journal of Gynecology & Obstetrics*, 1999, 65(2): 129-135.

#### How to cite this article:

Alaarabiou A, Rabbani K, Louzi A and Finech B (2019) 'Acute Appendicitis in Pregnancy: 33 Cases', *International Journal of Current Medical and Pharmaceutical Research*, 05(11), pp 4671-4674

\*\*\*\*\*