

RIVAROXABAN IN VENOUS PULMONARY THROMBOEMBOLISM. THE FIRST EXPERIENCE OF NEW ORAL ANTICOAGULANT

Duygu Zorlu¹, Adem Dirican², Ali Ekber Atas³, Tugce Uzar⁴, Yagmur Saritas⁴, Pankina Ekaterina⁵ and Sevket Ozkaya⁶

¹Faculty of Medicine, Department of Pulmonary Medicine, Kirsehir, Turkey

²Department of Pulmonary Medicine, Samsun, Turkey

³Department of Cardiology, Samsun, Turkey

⁴Faculty of Medicine, Istanbul, Turkey

⁵Faculty of Medicine, Department of Pulmonary Medicine, Ufa, Russia

⁶Faculty of Medicine, Department of Pulmonary Medicine, Istanbul, Turkey

ARTICLE INFO

Article History:

Received 13th March, 2019

Received in revised form 11th

April, 2019

Accepted 8th May, 2019

Published online 28th June, 2019

Key words:

Pulmonary embolism, new oral anticoagulants, rivaroxaban

ABSTRACT

Background: With the advent of new oral anticoagulants for the treatment of deep-vein thrombosis and/or pulmonary embolism, a new era of oral anticoagulation for patients with venous thromboembolism has begun. Rivaroxaban is the first new oral anticoagulant to receive regulatory approval for the acute and continued treatment of deep-vein thrombosis and pulmonary embolism.

Methods: We aimed to investigate the effects of rivaroxaban in patients with pulmonary embolism.

Results: The ages of patients are varies between 34-84 years old and male/female ratio was 14/8. *The average length of ICU (intensive care unit) and hospital stays are 69.5 hours and 6 days, respectively. The treatment complications were seen in only two patients including nausea and minor gastrointestinal hemorrhage. Rivaroxaban treatment was stopped in patients with hemorrhage. There was no any major bleeding and recurrence or treatment failure.*

Conclusions: We think that the enoxaparin followed by rivaroxaban is effective, safe for long-term treatment in patients with pulmonary embolism. Also, rivaroxaban treatment doesn't require laboratory coagulation monitoring.

Copyright © 2019 Sevket Ozkaya., Adem Dirican and Ali Ekber Atas. This is an open access article distributed under the Creative Commons Attribution License, which permits unrestricted use, distribution, and reproduction in any medium, provided the original work is properly cited.

INTRODUCTION

Pulmonary embolism (PE) is a common disorder and an important cause of morbidity and mortality. PE occurs in approximately 650,000 patients annually in the US, of whom approximately 300,000 die. PE of ten arise from thrombus originating in the deep venous system of the lower extremities or pelvis. A blood clot dislodges and is swept into the pulmonary circulation and lodges in a pulmonary artery (1,2). The standard therapy for most patients with pulmonary embolism has been the administration of heparin, overlapped and followed by a vitamin K antagonist. This regimen is effective but complex (3-8). Recently developed oral anticoagulants that are directed against factor Xa or thrombin overcome some limitations of standard therapy, including the need for injection and for regular dose adjustments on the basis of laboratory monitoring(9). We aimed to investigate the effects of rivaroxaban in patients with pulmonary embolism.

PATIENTS AND METHODS

Total 22 patients diagnosed with acute pulmonary embolism with at the Departments of Chest Diseases of Samsun Medicalpark Hospital between June 2015 and June 2016. The treatment protocol; initiate therapy 1 mg/kg enoxparine sodium (Clexane[®]) SC q12hr during hospitalization in patients with non-massive pulmonary embolism and Alteplase (Actilyse[®]) in patients with massive pulmonary embolism. After the discharge, orally 15mg Rivaroxaban (Xarelto[®]) twice daily for first 21 days after the diagnosis and followed orally 20mg Rivaroxaban (Xarelto[®]) once daily up to six months. The initial treatment of patients with massive pulmonary embolism The results were retrospectively evaluated at Nov 2016. Demographic, clinic, radiologic and laboratory results of patients were assessed retrospectively. The study was performed in accordance with the ethical principles of the Good Clinical Practice guidelines and with applicable local regulatory requirements. All patients read the patient information form about the study procedure, and written informed consents were received.

*Corresponding author: Sevket Ozkaya

Faculty of Medicine, Department of Turkey, Pulmonary Medicine, Istanbul

RESULTS

Demographic characteristics of 22 patients participated in our study are shown in Table.

Table Characteristics of Patients

Characteristics	Results
Age, year	
Mean±SD	58.4±15.5
Min-max	34-84
Gender	
Female (n,%)	8(36.4)
Male (n,%)	14(63.6)
Predisposition	
No	12(54.5)
Immobility	6(27.3)
Recent Surgery	4(18.2)
Massive PE	2(1)
Hospitalization day, mean±SD	4.6±2.5
ICU (n, %)	6(27.2)
ICU stay day, mean±SD	3.6±1.03
Rivaroxaban day, mean±SD	153±33
Follow-up, day, mean±SD	332±35
Visit* count, mean±SD	5.3±1.4
Adverse event	2(1)
Nausea (n,%)	1(0.5)
Minor hemorrhage (n,%)	1(0.5)

ICU: Intensive Care Unit, Visit*: Visit after discharge

The ages of patients are varies between 34-84 years old and male/female ratio was 14/8. Pulmonary embolism diagnosis and response to treatment were made with contrast-enhanced Thoracic CT and transthoracic echocardiography (Figure 1-3).

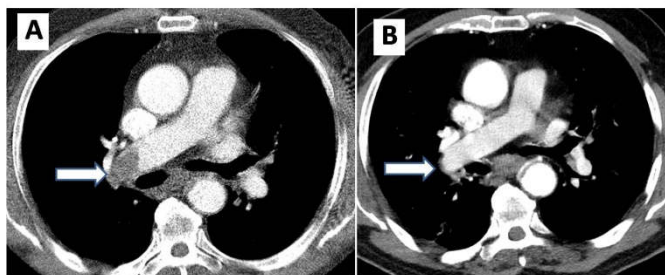


Figure 1 Thoracic CT images showing the acute pulmonary embolism in the right main pulmonary artery (arrow in A) and dissolution of blood clot at end of the treatment (arrow in B).

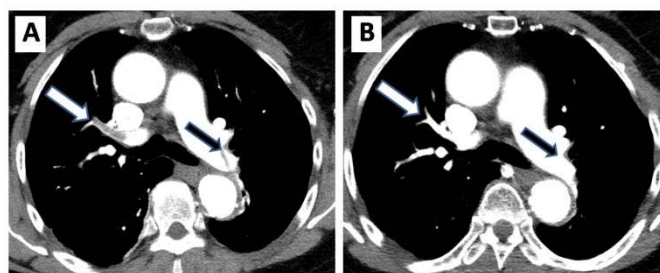


Figure 2 Thoracic CT images showing the acute pulmonary embolism in the right upper segmental pulmonary artery (white arrow in A) with left main pulmonary artery (black arrow in A) and dissolution of blood clots at end of the treatment (arrows in B).

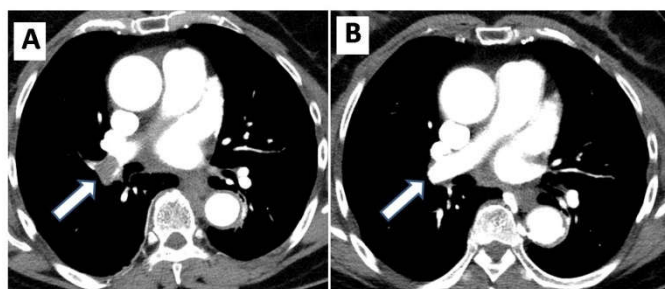


Figure 3 Thoracic CT images showing the acute pulmonary embolism in the right main pulmonary artery (arrow in A) and dissolution of blood clot at end of the treatment (arrow in B).

The massive pulmonary embolism diagnosed in two of patients which their ages were 75 and 82years old. The average length of ICU (intensive care unit) and *hospital* stays are 69.5 hours and 6 days, respectively. The treatment complications were seen in only two patients including nausea and minor gastrointestinal hemorrhage. Rivaroxaban treatment was stopped in patients with hemorrhage. - *The mean follow up duration* was 332 days. There was no any major bleeding and recurrence or treatment failure.

DISCUSSION

This is the first study involving hospitalized patients with pulmonary embolism, enoxaparin followed by rivaroxaban in Turkey. Rivaroxaban, an oral direct inhibitor of factor Xa, is effective and safe for the prevention of venous thromboembolism after major orthopedic surgery, for the prevention of stroke in patients with atrial fibrillation, and in the treatment of acute coronary syndromes (10-12). The EINSTEIN-PE program evaluated the concept of using rivaroxaban alone for anticoagulant therapy for acute deep-vein thrombosis and pulmonary embolism, replacing both heparin and vitamin K antagonists (13, 14). Their findings supported the use of rivaroxaban as a single oral agent for patients with venous thromboembolism. In our study, we report the availability of rivaroxaban in hospitalized patients with pulmonary embolism after enoxaparin, instead of warfarin. All patients diagnosed with contrast-enhanced thoracic CT and they were re-evaluated with contrast-enhanced thoracic CT at 6th months of treatment. There was no treatment failure according to contrast-enhanced thoracic CT at 6th months. Minor bleeding and nausea were noted as adverse event (%1) in our study. In EINSTEIN-PE study, adverse event rate was reported as 4.6%. In addition, two of our patients had massive pulmonary embolism and they were treated with thrombolytic treatment followed by rivaroxaban. There was no any complication noted in both of them. Although the our patient count is very small, this is the first and preliminary study of treatment with rivaroxaban in hospitalized patients with pulmonary embolism after enoxaparin, instead of warfarin.

Büller *et al.*, reported the enoxaparin followed by new oral anticoagulant in patients with symptomatic pulmonary embolism and they concluded the new oral anticoagulants could provide an attractive alternative to warfarin for the long-term treatment of pulmonary embolism, and seems to be associated with reduced bleeding, like our study(15).

Schulman *et al.*, investigated the unfractionated heparin administered intravenously or low-molecular-weight heparin administered subcutaneously followed by dabigatran in 30 patients with venous thromboembolism, like us. They suggested that the or the treatment of acute venous thromboembolism, a fixed dose of dabigatran is as effective as warfarin, has a safety profile that is similar to that of warfarin, and does not require laboratory monitoring(16).

In conclusion; we think that the enoxaparin followed by rivaroxaban is effective, safe for long-term treatment in patients with pulmonary embolism. Also, rivaroxaban treatment doesn't require laboratory coagulation monitoring.

Disclosure

"The authors have no conflicts of interest to declare".

References

1. Dirican A, Ozkaya S, Atas AE, Ulu EK, Kitapci I, Ece F. Thrombolytic treatment (alteplase; rt-Pa) in acute massive pulmonary embolism and cardiopulmonary arrest. *Drug Design, Development and Therapy* 2014;8:759-763.
2. Horlander KT, Mannino DM, Leeper KV. Pulmonary embolism mortality in the United States, 1979-1998: an analysis using multiple-cause mortality data. *Arch Intern Med.* 2003; 163(14):1711-1717.
3. Barritt DW, Jordan SC. Anticoagulant drugs in the treatment of pulmonary embolism: a controlled trial. *Lancet* 1960; 1: 1309-12.
4. Kearon C, Akl EA, Comerota AJ, *et al.* Antithrombotic therapy for VTE disease: Antithrombotic Therapy and Prevention of Thrombosis, 9th ed.: American College of Chest Physicians Evidence-Based Clinical Practice Guidelines. *Chest* 2012; 141: Suppl: e419S-e494S.
5. Simonneau G, Sors H, Charbonnier B, *et al.* A comparison of low-molecularweight heparin with unfractionated heparin for acute pulmonary embolism. *N Engl J Med* 1997; 337:663-9.
6. The Matisse Investigators. Subcutaneous fondaparinux versus intravenous unfractionated heparin in the initial treatment of pulmonary embolism. *N Engl J Med* 2003; 349:1695-702. [Erratum, *N Engl J Med* 2004; 350:423.]
7. Büller HR, Gallus AS, Pillion G, Prins MH, Raskob GE. Enoxaparin followed by once-weekly idrabiotaparinux versus enoxaparin plus warfarin for patients with acute symptomatic pulmonary embolism: a randomised, double-blind, double-dummy, non-inferiority trial. *Lancet* 2012; 379: 123-9.
8. The van Gogh Investigators. Idraparinux versus standard therapy for venous thromboembolic disease. *N Engl J Med* 2007; 357:1094-104.
9. The EINSTEIN-PE Investigators. Oral Rivaroxaban for the Treatment of Symptomatic Pulmonary Embolism. *N Engl J Med* 2012; 366:1287-1297.
10. Turpie AG, Lassen MR, Eriksson BI, *et al.* Rivaroxaban for the prevention of venous thromboembolism after hip or knee arthroplasty: pooled analysis of four studies. *Thromb Haemost* 2011; 105:444-53.
11. Patel MR, Mahaffey KW, Garg J, *et al.* Rivaroxaban versus warfarin in nonvalvular atrial fibrillation. *N Engl J Med* 2011; 365:883-91.
12. Mega JL, Braunwald E, Wiviott SD, *et al.* Rivaroxaban in patients with a recent acute coronary syndrome. *N Engl J Med* 2012; 366:9-19.
13. The EINSTEIN Investigators. Oral rivaroxaban for symptomatic venous thromboembolism. *N Engl J Med* 2010;363:2499- 510.
14. Buller HR, Lensing AW, Prins MH, *et al.* A dose-ranging study evaluating oncedaily oral administration of the factor Xa inhibitor rivaroxaban in the treatment of patients with acute symptomatic deep vein thrombosis: the Einstein-DVT DoseRanging Study. *Blood* 2008; 112:2242-7.
15. Büller HR, Gallus AS, Pillion G, Prins MH, Raskob GE. Enoxaparin followed by once-weekly idrabiotaparinux versus enoxaparin plus warfarin for patients with acute symptomatic pulmonary embolism: a randomised, double-blind, double-dummy, non-inferiority trial. *Lancet* 2012; 379: 123-9.
16. Schulman S, Kearon C, Kakkar AK, *et al.* Dabigatran versus warfarin in the treatment of acute venous thromboembolism. *N Engl J Med* 2009; 361:2342-52.

How to cite this article:

Duygu Zorlu *et al* (2019) ' Rivaroxaban in Venous Pulmonary Thromboembolism. the first Experience of new oral Anticoagulant', *International Journal of Current Medical And Pharmaceutical Research*, 05(06), pp 4277-4279.
