ISSN: 2395-6429

INTERNATIONAL JOURNAL OF CURRENT MEDICAL AND PHARMACEUTICAL RESEARCH

IJCMPR

Available Online at http://www.journalcmpr.com

DOI: http://dx.doi.org/10.24327/23956429.ijcmpr20170062

CASE REPORT

ENDODONTIC MANAGEMENT OF SPECIAL CARE PATIENTS WITH ACCESS DIFFICULTIES: A CASE OF ORAL SUBMUCOUS FIBROSIS AND A TEMPOROMANDIBULAR JOINT ANKYLOSIS

Manoj Mahadeo Ramugade

Department of Conservative Dentistry and Endodontics, Govt. Dental College and Hospital, Mumbai, ST. George Hospital Compound, P. D'mello Road, Fort, Mumbai

ARTICLE INFO

Article History:

Received 18th February, 2017
Received in revised form 10th March, 2017
Accepted 20th April, 2017
Published online 28th May, 2017

Key words:

Endodontic management, anatomical difficulties, OSMF, TMJ ankylosis.

ABSTRACT

Endodontic management of diseased pulp consist of cleaning and shaping of root canal after adequate access and thus sealing of the root canal space with inert obturating material. Root canal treatment has been considered as a challenging task when teeth are associated with anatomical difficulties such as root canals with extreme curvature, calcification or aberrant root anatomy etc. These difficulties become more complex when access to the tooth is limited as in case of limited mouth opening associated with oral submucous fibrosis (OSMF) and temporomandibular joint (TMJ) disorder. This article describes the successful endodontic management of two complex cases of patient having OSMF and patient with TMJ ankylosis.

INTRODUCTION

Endodontic treatment consist of triad of access cavity preparation, cleaning and shaping of the root canals along with irrigation and obturation of prepared root canal space with biologically acceptable inert filling material. Endodontics becomes challenging venture when it is associated with multiple canals, lateral exits, curve canals and canal calcifications etc. All these difficulties could be successfully managed once straight line access to apical terminus is achieved and canal patency is maintained. In unusual cases when there is restriction for access to tooth to be treated, root canal treatment becomes more difficult to impossible. The presented case report elaborates successful endodontic management of two patients, one with OSMF and other with TMJ ankylosis.

Case report 1: Endodontic management in OSMF patient

A 35 years male patient was referred from a private dentist to Department of Conservative Dentistry and Endodontics, complaining of pain in mandibular right posterior teeth since 2 weeks and burning sensation in the oral cavity. His medical history was uncontributory and presented with restricted mouth opening. He visited to a private dental practitioner for the treatment of decayed teeth # 45 and # 46, for which intra oral periapical (IOPA) radiograph was taken. The root canal treatment was started in tooth #45 and analgesics, antibiotics were prescribed. The patient was then referred to our department for further treatment due to limited mouth opening. On clinical examination, patient presented with pain in tooth #45, #46 with only mouth opening upto 2 fingers. Patient gave history of betal nut chewing for past 14 years and complaining of burning sensation in oral cavity since 5 years. Patient showed blanching of oral mucosa and presence of fibrous bands all over cheek and lip mucosa causing restricted mouth opening. His cheek flexibility was measured from the maxillary incisal midline to the cheek retractor during retraction which showed reduced flexibility to 22mm.[1] Patient was diagnosed with oral submuous fibrosis (OSMF) of oral mucosa. Intraoral examination revealed poor oral hygiene with multiple carious teeth including teeth #45 and #46. Preoperative IOPA revealed aberrant anatomy of roots of both teeth. Tooth #45 showed two roots with 2 canals and tooth #46 showed three roots with 4 canals. All roots of tooth #46 showed moderate distal curvature in apical 1/3rd (Figure 1).

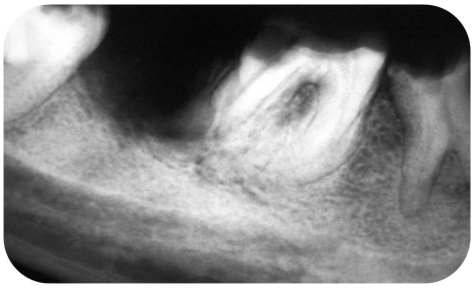

Figure 1 Preoperative IOPA of teeth #45 and #46

After obtaining informed consent of patient, under possible isolation access was achieved in tooth #45 and #46. In tooth #45 canal orifices were located but could not be negotiated further beyond coronal third of the root canal even under 8x magnifications. Considering the remaining tooth structure and non negotiable root canals, extraction of tooth #45 was advised after completing root canal of tooth #46. Root canals were explored in tooth #46 and working length was estimated using apex locator due to inability to take working length radiograph in limited mouth opening. Root canals were felt to be narrow and patency was established with No. 10 C file. Further preparation was done using files no. 15 and No. 20 modified by giving bent at desired angle (Figure 2).

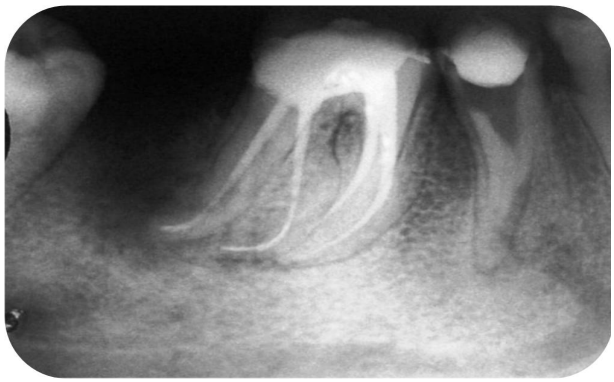

Figure 3 Postoperative IOPA of teeth #45 and #46

Coronal flaring was done with orifice opener file, Protaper Sx and canal preparation was completed sequentially upto 6% no.20 Protaper files. Obturation was completed with 6% Protaper standardized gutta percha with AH plus sealer and post operative radiograph was taken (Figure 3). Patient was scheduled for thorough scaling, restoration of other carious teeth, extraction of tooth #45 and permanent restoration of tooth #46 after a week. After extraction fixed prosthesis was advised to the patient.

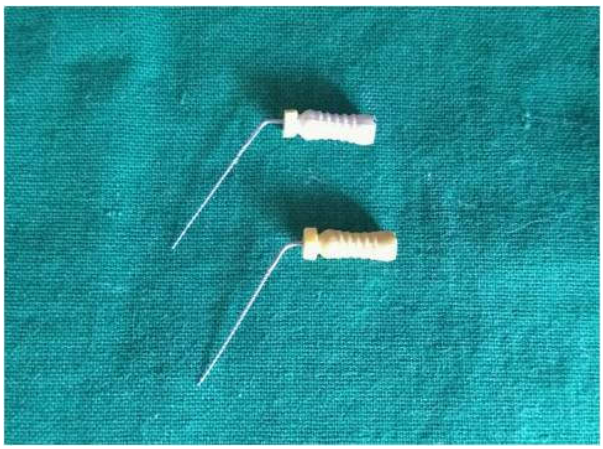

Figure 2 Modified files No. 15 and No. 20- K files bent at an angle to get access into root canals.

Case report 2: Endodontic management of patient with TMJ ankylosis

A 43 years female patient was referred from a private dentist to Department of Conservative Dentistry and Endodontics complaining of pain in mandibular right posterior tooth since 5 days. Patient was presented with restricted mouth opening and bilateral ankylosis of temporomandibular joint and was on anticoagulant therapy for arterial sclerosis. Patient gave history of rheumatoid arthritis and had continuous, throbbing pain in the carious tooth #46 since 5 days for which she visited to a private dental practitioner. The dentist started root canal treatment in tooth #46 and prescribed analgesics and antibiotics. But due to inadequate mouth opening and associated medical conditions patient was referred for completion of further treatment.

On examination, patient presented with only 2 fingers opening about 10mm and gave history of temporomandibular (TMJ) ankylosis since childhood for which she has been operated but no improvement was observed. Intraoral examination revealed poor oral hygiene with access preparation in tooth #46 having amalgam restoration. After obtaining medical consent from the cardiologist and informed consent of patient for root canal treatment, patient was pre-medicated with antibiotics and analgesics.

Under possible isolation and using high vacuum suction, the prepared access cavity was modified adhering to principles of access cavity preparations. The working length IOPA was taken with great difficulty which revealed that, the tooth which is under treatment was in fact tooth #47 instead of #46 (Figure 4).

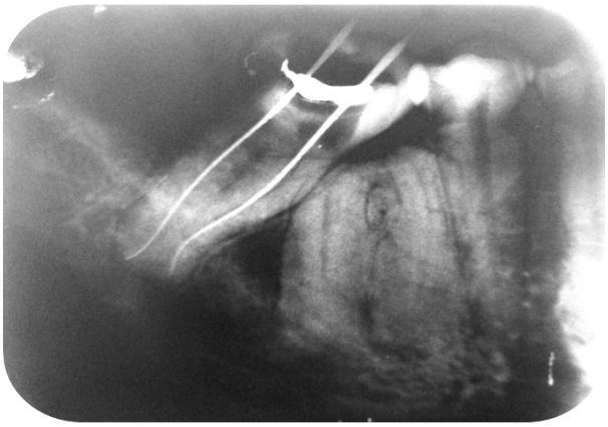

Figure 4 Working length IOPA of tooth #47, showing submerged #46.

The crown of tooth #46 was broken down severely and seemed to be submerged and ankylosed beneath the crown of tooth #47. The tooth #47 was migrated mesially, giving a false impression of being tooth #46. Two canals were observed and the roots were unusually curved and longer having working length measuring about 23.5mm in length. Due to restricted access to prepare root canals, patency was established with no. 10K (Kerr file) till working length. Coronal flaring was done with Protaper Sx file.

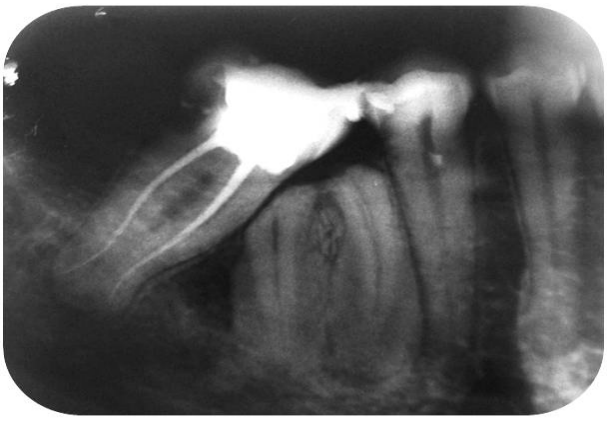

Figure 5 Post operative IOPA of tooth #47.

Copious irrigation was done using 5.2% sodium hypochlorite during entire cleaning and shaping procedure. Hand files were modified as per requirement of the case by bending files at an angle to get access into the canals (Figure 2). Canal preparation was started using No. 20, 2% rotary NiTi Hero shaper files. Final apical preparation was completed using No. 25, 4% Hero shaper NiTi rotary files. Obturation was done using AH Plus sealer and No. 25, 4% standardized gutta percha point. Post operative radiograph was taken with difficulty (Figure 5) and patient was advised permanent restoration in tooth #47 followed by crown. The tooth #46 root piece was kept under observation.

DISCUSSION

Root canal treatment has not always been simple task even for an Endodontist. Routinely cases were referred to Endodontist due to canal difficulty or unusual anatomy. But sometimes cases presented with greater level of difficulty when associated with multiple factors. Some of the difficult cases for access to root canal are patient with OSMF or TMJ disorder when mouth opening is restricted by anatomical factors.

OSMF is a potentially malignant disease of oral cavity, clinically characterized by progressive inability to open mouth. It is considered as precancerous condition of oral mucosa predominantly in Indian subcontinents and South-east Asia. Its overall prevalence rate is found to be 0.2% to 0.5% in India.[2,3.] Multiple factors were reported to be associated with OSMF such as, betal nut (areca nut) chewing in 73.3%[4], ingestion of chilies, nutritional deficiency, autoimmunity, genetic disorder, collagen disorders and altered salivary constituents. OSMF is usually characterized by burning sensation, blanching and stiffening of oral mucosa, reduced tongue movement with depapillation and progressive reduction of mouth opening.[5,6] Normal cheek flexibility as observed in males was 35-45 mm and 30-40 mm in females but, it was 24mm in our case.[1] OSMF is considered to have high degree of malignant potential ranges between 2.3% to 7.6%.[7] Treatment of OSMF aims at stoppage of betal nut or tobacco chewing habit and symptomatic improvement in mouth opening.[8]

Endodontic treatment in OSMF patient becomes challenging task requiring patience. In our case of OSMF, we could take limited IOPA due to inability to place IOPA film in oral cavity. Radiovisiography sensor was stiff enough to place at desired position in oral cavity without restriction and pain to the patient. Root canal preparation of tooth #46 was completed by modifying files as per need of the case. Once patency was established to the apical terminus in all canals having moderate apical curvature, cleaning and shaping was completed using more flexible NiTi instruments like protapers. In this case tooth #45 was attempted for root canal treatment but root canals were found be non-negotiable. Considering overall prognosis of tooth #45, extraction was advised followed by its replacement. Due to limited mouth opening and presence of burning sensation of oral mucosa, patient avoided oral hygiene care leading to poor oral hygiene and more number of carious teeth as observed in our case.

TMJ ankylosis is a pathologic condition due to fusion of mandibular condyle to the fossa by bony or fibrotic tissue. Trauma and infection are one of the major factors associated with TMJ disorder.[9,10,11] Systemic causes of TMJ ankylosis include ankylosing spondylitis, rheumatoid arthritis and psoriasis.[12] Clinically TMJ ankylosis is characterized by restricted mouth opening and jaw movement, mandibular retrognathism, facial asymmetry if affected unilaterally and malaligned teeth with poor oral hygiene. In unilateral TMJ ankylosis, chin deviates on the affected side on mouth opening whereas; in bilateral TMJ ankylosis leads to restricted mouth opening without deviation of chin.

In presented case, taking periapical radiograph was difficult due to limited access into oral cavity. Working length IOPA was taken with great difficulty revealed that, the crown of tooth #46 was broken down and roots were submerged and ankylosed beneath the crown of tooth #47. The tooth which is under treatment was in fact tooth #47 and misinterpreted as #46. Due to mesial tilting of the tooth #47 it was giving a false impression of being tooth #46. Thus radiograph plays vital role in such difficult cases to reveal underlying anatomy as in this case. In this case limited access caused difficulty in canal preparation which has overcome by modifying files as per the case and using NiTi instruments. As root of tooth #46 was submerged and patient was asymptomatic and having known medical problem, it was kept under observation without any intervention.

Maintenance of oral hygiene becomes critical in such patients with limited access to clean all teeth. Regular chlorhexidine and fluoride rinses should be advised, especially in cases where it is not possible to reach the posterior teeth and lingual, palatal surfaces by traditional brushing methods due to limited mouth opening. Timely periodontal and restorative treatment, the use of high-dose fluoride toothpaste and recurrent topical fluoride applications help to prevent the development of oral and dental diseases especially in children and adolescent.

CONCLUSION

Treating the patients with difficulty in mouth opening due to anatomical or pathological condition are the challenging tasks for the dentist including Endodontist. Special consideration should be given while attempting such cases by general dentist and refer the cases to specialist whenever indicated. Endodontist due to higher level of skills and training could manage such cases of root canal treatment in OSMF and TMJ disorder without much effort. Root canal preparation could be done slowly by giving sufficient time for patient to relax his oro-facial muscles and close his mouth in between the treatment, thus reduces post operative pain.

References

1. Susarla SM, Dodson TB. Risk factors for third molar extraction difficulty. *J Oral Maxillofac Surg.* 2004; 62:1363-71.
2. Khan S, Chatra L, Prashanth SK, Veena KM, Rao PK. Pathogenesis of oral submucous fibrosis. *J Cancer Res Ther.* 2012; 8:199-203.
3. Yoithapprabhunath TR, Maheswaran T, Dineshshankar J, Anusushanth A, Sindhuja P, Sitra G. Pathogenesis and therapeutic intervention of oral submucous fibrosis. *J Pharm Bioallied Sci.* 2013; 5:S85-S88.
4. Santosh Patil, Sneha Maheshwari, *J. Clin Exp Dent* 2014; 6(3) e255-8
5. More CB, Das S, Patel H, Adalja C, Kamatchi V, Venkatesh R. Proposed clinical classification for oral submucous fibrosis. *Oral Oncol.* 2012; 48:200-2.
6. Tilakaratne WM, Klinikowski MF, Saku T, Peters TJ, Warnakulasuriya S. Oral submucous fibrosis: review on aetiology and pathogenesis. *Oral Oncol.* 2006;42:561-8.

7. Canniff JP, Harvey W. The aetiology of oral submucous fibrosis: the stimulation of collagen synthesis by extracts of areca nut. *Int J Oral Surg*. 1981; 10:163-7.
8. Chole RH, Gondivkar SM, Gadbail AR, Balsaraf S, Chaudhary S, Dhore SV. Review of drug treatment of oral submucous fibrosis. *Oral Oncol.* 2012; 48:393-8.
9. Straith CL, Lewis JR. Ankylosis of the temporomandibular joint. *Plast Reconstr Surg* 1948; 3:464-6.
10. Miller GA, Page HL Jr, Griffith CR. Temporomandibular joint ankylosis: review of the literature and report of 2 cases of bilateral involvement. *J Oral Surg* 1975; 33(10):792-803.
11. Topazian RG. Etiology of ankylosis of the temporomandibular joint: analysis of 44 cases. *J Oral Surg* 1964; 22:227-33.
12. Fonseca RJ. Oral and Maxillofacial Surgery: Temporomandibular Disorders. Philadelphia (PA): W.B. Saunders Company; 2000. p. 309-13.

****