



ISSN: 2395-6429

## CURCUMIN GUM: USE OF PHOTODYNAMIC THERAPY IN CHILDREN WITH ACUTE PHARYNGOTONSILLITIS

Kate C. Blanco<sup>1\*</sup>, Andre L. Giusti<sup>2</sup>, Natalia M. Inada<sup>1</sup> and Vanderlei S. Bagnato<sup>1</sup>

<sup>1</sup>University of São Paulo, São Carlos Institute of Physics, São Carlos, São Paulo, Brazil

<sup>2</sup>Department of Medicine, Federal University of São Carlos, São Carlos, São Paulo, Brazil

### ARTICLE INFO

#### Article History:

Received 14<sup>th</sup> February, 2017

Received in revised form 8<sup>th</sup>

March, 2017

Accepted 27<sup>th</sup> April, 2017

Published online 28<sup>th</sup> May, 2017

#### Key words:

Doctor, Doctor-patient relationship,  
Consumer Protection Act, Consumer  
forum

### ABSTRACT

Group A *Streptococcus* (GAS) is responsible for 30% of acute pharyngitis in children<sup>1</sup>. An estimated 600 million cases occur annually in over 4 years of age and more than 90% of disease cases occur in developing countries<sup>2</sup>. The antimicrobial susceptibility of pathogenic strains has been related to clinical informations in the treatment of pharyngotonsillitis due to antimicrobial resistance. Photodynamic Therapy (PDT) is a regularised treatment for cancer and other diseases. In PDT, non-toxic substances, the photosensitizer (PS) are accumulate preferentially in abnormal cells and microorganisms and photoactivated by visible light at specific wavelengths and reactive and oxygen species toxic to bacteria are generated. PDT presents advantages such as mechanisms for targeting of PS to microorganisms and non developed of bacterial resistance to drug. In two cases were studied the clinical and microbiological characteristics of treatment of acute pharyngitis in children using curcumin gum.

Copyright © 2017 Kate C. Blanco et al. This is an open access article distributed under the Creative Commons Attribution License, which permits unrestricted use, distribution, and reproduction in any medium, provided the original work is properly cited.

## INTRODUCTION

### Background

Sore throat is a common complaint in outpatient medical consultations and emergencies. Acute pharyngotonsillitis (PT) represents an important source of social disturbances in childhood such as missing classes. It may also lead to repeated use of antimicrobials and cause both local and systemic complications such as peritonsillar or retropharynx abscesses, otitis, sinusitis, pneumonia, rheumatic fever and post streptococcal glomerulonephritis<sup>1</sup>.

Group A *Streptococcus* (GAS) is responsible for 20-40% of acute pharyngitis in children<sup>2</sup>. An estimated 600 million cases occur annually in children over 4 years of age, and more than 90 per cent of these cases occur in developing countries<sup>3</sup>. In the last two decades, we have witnessed the emergence and spread of bacteria resistant to multiple antibacterial agents<sup>4,5</sup>. Multiresistant bacteria are currently considered an emerging global disease and an important public health problem. Coordinated efforts are required for the development of new diagnostic and therapeutic strategies as well as new antimicrobial agents.

Photodynamic therapy (PDT) is a therapeutic modality that relies on photochemical and photophysical processes to induce cell death. The therapy involves three main components, the

visible light, a non-toxic photosensitizing substance (PS) and molecular oxygen. The wavelength of the visible light must match with the absorption spectrum of the PS, leading to the state of excitation that promotes production of reactive oxygen species. This phototoxic reaction induces the lysis of pathogenic microorganisms and of neoplastic cells<sup>6,7</sup>. It has been shown to be effective and safe in reducing bacterial counts of the oral cavity in both dental procedures and oral disinfection.

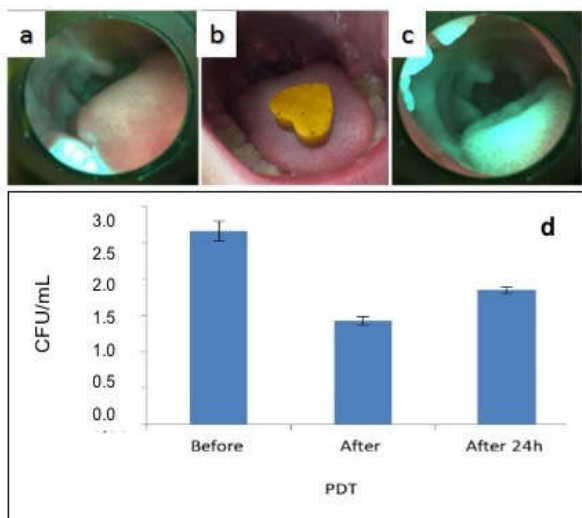
It was performed of efficiency verification of a new procedure for PT treatment in children PT. We describe a two cases with acute PT treated with PDT using a curcumin gum and an equipment recently developed.

### Case Reports

We performed a PDT of the oral cavity using as photosensitizer a 0.75% curcumin gum (PDT Pharma, Brazil) and a device based on blue light-emitting diode (LED) (450 nm) with transparent acrylic curved diffuser tip. We used an illumination intensity of 18 mW/cm<sup>2</sup> and 2.2 J/cm<sup>2</sup> in the mucosa of the tonsils and pharynx. The device is formed by a set of optical fibers that guarantees a uniform hemispherical illumination due to its conical shape. The child chewed the curcumin gum for 1 minute and 20 seconds (Figure 1 b-c) and then received the illumination for 1 minute and 30 seconds (Figure 2-a).

### Case A

A 5-year-old boy was brought by her mother to medical consultation with a one-day history of fever and sore throat. He was a previous health boy, and denied cough. His mother would like to avoid the use of antibiotics. Clinically, the child presented red tonsils with pus on them.



**Figure 1** Case A. Auto fluorescence (a); gum (b); fluorescence after gum (c); bacterial reduction before and after PDT (d)

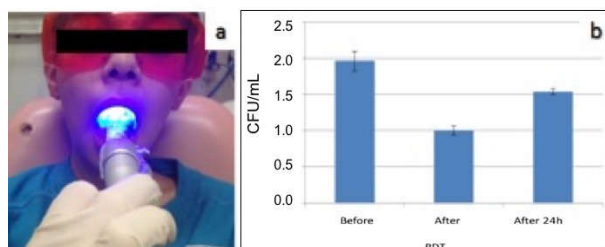
It is possible to observe the difference of fluorescence before (Figure 1-a) and after (Figure 1-c) gum. The increased fluorescence is visualized with the Evinco device (MMOptics, 405nm) in Figure 1-c. Curcumin (in green) is activated in mucosa after consumption of the gum by illumination.

Before and after the PDT, Swabs were collected for analysis of bacterial colony-forming unit counts (UFC). A clinical and microbiological evaluation were performed immediately and 24h after. The microbial results showed that there was a decrease of 1 Log<sub>10</sub> of bacteria after the treatment, and there was no recolonization after 24h (Figure 1-d).

In the second treatment sessions was not necessary due no symptoms 24h after treatment. It was observed absence of exudate as well as reduction of temperature (36.6°C) 24h after treatment.

### Case B

A 13-year-old boy was to medical consultation with her mother and a history of inappetence, prostration, pustules in tonsils and fever at 39°C for three days. The clinical picture is characterised by signs of bacterial PT.



**Figure 2** Case B: Illumination in PDT (a); bacterial reduction before and after PDT (b).

The microbial reduction was around of 1 Log<sub>10</sub> of CFU after the treatment and there was no recolonization after 24h (Figure

1-b). Fever control and odynophagia was observed after 24h. However, 48h after treatment no symptom was reported.

### DISCUSSION

Infection treatments caused by microorganisms can be performed by topical and systemic medications<sup>5</sup>. Topical treatment has few side effects and cannot interact with other systemic drugs. However, these antiseptics can be ineffective with low rate of penetration in infected region. Thus the formulation used (gum) provided the delivery of PS in the tonsils and pharynx, especially in children, where pathogenic bacteria are located.

The antibiotic is widely used in the treatment of diseases caused by microorganisms. However, in addition to problem of bacterial resistance with the use of antibiotics, these drugs can cause adverse effects such as diarrhea<sup>6</sup>, headache<sup>7</sup> and mouth sores<sup>8</sup>. PDT is a local treatment that not cause side effects and in addition does not cause antimicrobial resistance. PDT may also be an alternative to treatment of viral PT. PDT has been applied in viral lesions of Herpes simples located in mouth and genitals since 1970.

It is necessary that the light reaches the places where the pathogenic bacteria are located for the treatment to be successful. The device developed by São Carlos Institute of Physics is designed to light tonsils and pharynx and it is pleasant to patients. The light is reflected in the oral mucosa of pharynx and tonsils because the critical angle is promoted with the total reflection of rays. This is possible due to rough surface of this tip that diffuses rays and reaches these places. The diffuser tip has a diffusion optic that diffuses light homogeneously over a given diameter.

Considering the importance of the emergence of new therapies due to antimicrobial resistance we demonstrated in this study the importance of PDT for treatment of streptococcal pharyngitis. This innovation in treatment can influences clinical practices, prototypes and formulations. With the continuity of applications in this area, a new form of decontamination and treatment of these infections can be legitimized and with the continuity of applications in this area, a new form of decontamination and treatment of these infections can be legitimized and be used to avoid the recurrent use of antibiotics.

### Acknowledgements

This study was supported by São Paulo Research Foundation (FAPESP: CEPOF Grant n° 13/07276-1).

### References

1. Wessels, M. R. Streptococcal Pharyngitis. *N. Engl. J. Med.* 2011, 648.
2. Ba-Saddik, I. A.; Munibari, A. A.; Alhilali, A. M.; Ismail, S. M.; Murshed, F. M.; Coulter, J. B. S.; Cuevas, L. E.; Hart, C. A.; Brabin, B. J.; Parry, C. M. Prevalence of Group A Beta-Haemolytic Streptococcus Isolated from Children with Acute Pharyngotonsillitis in Aden, Yemen. *Trop. Med. Int. Heal.* 2014, 19 (4), 431.
3. Weber, R. Pharyngitis. *Prim. Care Clin. Off. Pract.* 2013.
4. Aparecida, M.; Palos, P. Staphylococcus Aureus E Staphylococcus Aureus Meticilina Resistentes (MRSA) Em Profissionais de Saúde E as Interfaces Com as Infecções Nosocomiais Staphylococcus Aureus E Staphylococcus Aureus Meticilina Resistentes (MRSA)

- Em Profissionais de Saúde E . 2006.
5. Giedraitienė, A.; Vitkauskienė, A.; Naginienė, R.; Pavilonis, A. Antibiotic Resistance Mechanisms of Clinically Important Bacteria. *Medicina (Kaunas)*. 2011, 47 (3), 137.
  6. Hamblin, M. R.; Hasan, T. Photodynamic Therapy: A New Antimicrobial Approach to Infectious Disease? *Photochem. Photobiol. Sci.* 2004, 3 (5), 436.
  7. Braham, P.; Herron, C.; Street, C.; Darveau, R. Antimicrobial Photodynamic Therapy May Promote Periodontal Healing through Multiple Mechanisms. *J. Periodontol.* 2009, 80 (11), 1790.

\*\*\*\*\*