



RETRIEVAL OF FRACTURED-IMPLANT USING A ULTRASONIC TECHNIQUE: A CASE REPORT

Prakash Vhatkar., Tejaswini Patil and Kiran Suradkar

Department of Periodontology Bharati Vidyapeeth Deemed University Dental College Pune

ARTICLE INFO

Article History:

Received 20th June, 2017

Received in revised form 3rd

July, 2017

Accepted 27th August, 2017

Published online 28th September, 2017

Key words:

Dental implant, screw loosening,
osseointegration.

ABSTRACT

Implant restorations can fail biologically or mechanically. Biological factors include unsuccessful osseointegration or presence of peri-implantitis. Mechanical failures include crown fracture, framework fracture, and screw loosening, and screw fracture. Fracture of the implant abutment can be a serious problem as the fragment remaining inside the implant may prevent the implant from functioning efficiently. The procedure used for removal of the fractured screw portion is described in this clinical report.

Copyright © 2017 Prakash Vhatkar et al. This is an open access article distributed under the Creative Commons Attribution License, which permits unrestricted use, distribution, and reproduction in any medium, provided the original work is properly cited.

INTRODUCTION

Clinicians have for many decades attempted to replicate teeth by implanting alloplasts into bone. Scientifically based implant therapy, however, emerged at the end of the 1970s following groundbreaking studies with 10-year clinical results presented by a research group in Sweden directed by Dr P-I Branemark.

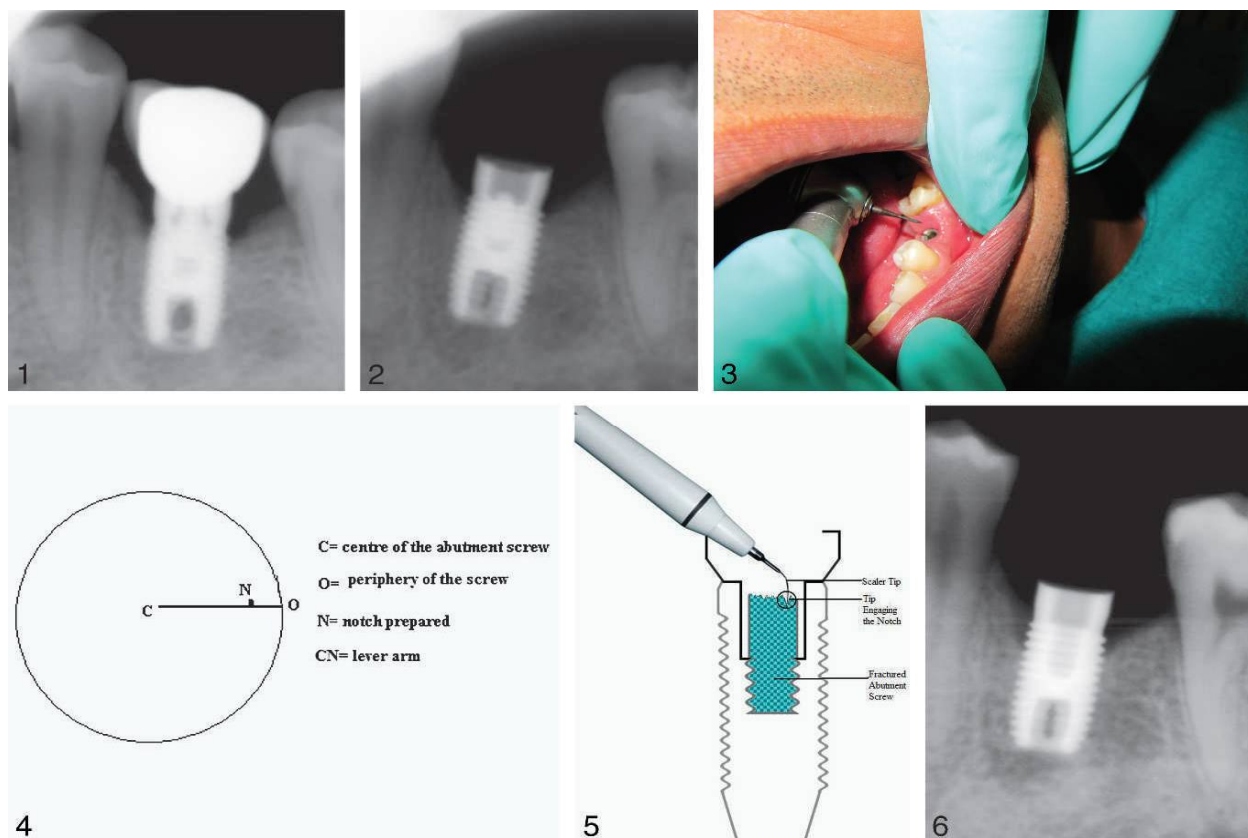
1. Implant therapy is an effective and reliable restorative Treatment option.
2. The success of dental implants is based primarily on the extent of osseointegration. Implant restorations can fail biologically or mechanically. Biological factors include unsuccessful osseointegration or the presence of peri-implantitis.
3. Mechanical failures include crown fracture, framework fracture, screw loosening, and screw fracture.⁴

The most common fracture is of the hexagonal head away from the main body of the screw.⁵ A loose screw is more prone to excessive sideways load. Fracture of the implant abutment screw can be a serious problem as the fragment remaining inside the implant may prevent the implant from functioning efficiently. In a recent study by Kreissl et al, the incidence over a 5-year period of abutment screw fracture was 3.9% and that of abutment screw loosening was 6.7%.⁶ Screw loosening was reported as the most common complication in a follow-up study of 76 Branemark single-tooth implants.⁷

Implant components are known to fracture more frequently in the posterior region and in partially dentate patients compared with completely edentulous patients.^{8,9} The average Occlusal

masticatory force was reported to be between 450 N and 550 N in patients who were completely dentate to the second premolar. A decrease of the occlusal force to a level between 200 N and 300 N was recorded for fixed as well as for removable implant-supported restorations. Implant abutments fail when lateral forces exceed 370 N for abutments with a joint depth of at least 2.1 mm and 530 N with a joint depth of at least 5.5 mm.^{10,11} Joint depth in implant systems is of significant importance for the resistance to bending loads.¹² The primary reason for screw fracture is undetected screw loosening, which can be due to bruxism, an ill-fitting superstructure, or overloading.

Frequent screw loosening can be a risk factor for dental implant fracture, indicating that a change in the prosthesis design should be undertaken.^{1,3} Many methods have been reported for retrieving screw fragments within the implant. Two common approaches are (1) the use of a self-made screwdriver or (2) the use of a service set available for the specific implant system.^{4,14} If the fragment is not jammed, an attempt to unscrew it using an explorer or a straight probe might be successful. The tip of the instrument is moved carefully in a counterclockwise direction over the surface of the screw Segment until it loosens. An implant repair kit (ITI) Dental Implant System, Institute Straumann, Waldenburg, Switzerland) is also available and consists of drills, 2 drill guides, and 6 manual tapping instruments. One drill is 1.6 mm in diameter and is used counterclockwise at a speed of at least 600rpm, together with the respective drill guide.



Figures 1 6

- Figure 1** Radiograph of fractured screw with the crown.
- Figure 2** Radiograph of fractured screw after crown removal.
- Figure 3** Tapered Tri Hawk bur to prepare the notch.
- Figure 4** Diagram showing central axis and notch position.
- Figure 5** Diagram showing scaler tip engaged in the notch.
- Figure 6** Radiograph after the screw removal.

Once the fragment has been perforated, the 6 manual tapping instruments are used successively with the second drill guide in a clockwise direction to remove the retained fragment and to section the threads. This procedure will not unscrew the fractured fragment. It will cut it into splinters while cutting the threads at the same time, leading to the misfit of the new abutment screw.⁴ The method is complex for routine application and involves the risk of damaging the internal threads of the implant. The use of the repair system may not be successful in different situations. Screwing out the fragment is a better method as it will leave the implant threads intact. It is essential not only to retrieve the fractured screw but also to determine the reason for failure and to modify the prosthesis if necessary.

CASE REPORT

A 26-year-old man reported to our dental clinic with a loosened crown on the mandibular left first molar, which was cemented over an implant abutment 6 years back. The clinical impression was of a loosened abutment screw but later was radiographically evaluated and was found to be associated with abutment screw fracture. There was radiographic evidence of marginal bone loss (Figure 1). Clinically, the ceramic was seen to be chipped off occlusally. A Zimmer Screw Vent straight implant of (4.7 mm D3 ,10 mm L; Zimmer, Carlsbad, Calif) was placed 6 years back, and the crown was cement retained. The patient did not come for follow-up during this period of 6 years.

It was decided to remove the crown and retrieve the fractured portion of the screw using a modified technique with an ultrasonic scaler (EMS, Dallas, Tx). An access hole was made occlusally through the crown by a Tri Hawk carbide bur (Tri Hawk Corporation, Massena, NY) to access the screw head and retrieve the crown along with the abutment. Once the crown and abutment were removed, a radiograph was taken to reconfirm the fractured part of the abutment screw inside the implant (Figure 2). A fine tapered carbide bur (Tri -Hawk) was used to make a notch on the occlusal surface of abutment screw between the center of the screw and its periphery (Figure 3). Care was taken not to touch the internal threads of the implant with the bur, and at the same time the notch was not at the center (Figure 4). An ultrasonic scaler tip was then inserted into the implant and was made to engage the notch created (Figure 5). The ultrasonic scaler was started at a very low speed, and mechanically the tip of the scaler was moved counterclockwise. After the retrieval of the broken part of the abutment screw, a radiograph was taken to reconfirm its complete removal (Figure 6).

DISCUSSION

The present situation illustrates some of the complications inherent in the use of implant components. The abutment screw fracture as observed in this case is one of the most common complications seen. The reason for the screw fracture was assumed to be the unrecognized loosening of the screw aggravated by nonaxial movements during prosthetic loading,

culminating in the fracture. Other possible reasons for screw loosening can be a defect in the screw itself, that the screw may have been over torqued on insertion, or that the abutment may not have been fully seated when the torque was applied to the screw, resulting in increased stress. Reduced interocclusal distance and inefficiency of the operator can also result in screw fracture.

Several techniques of removal of a broken abutment screw have been documented, such as engaging an endodontic explorer or a straight probe and ultrasonic scaler. Special screw retrieval systems are also being supplied by various implant manufacturers. Systems such as Ankylos have a Morse Taper, which eliminates the need of a screw for retention and antirotation. In the described clinical situation, the broken abutment screw could not be moved by an explorer or ultrasonic scaler tip. So a notch was created over the abutment head between the center of the screw and its periphery for the mechanical interlocking of scaler tip and screw head. This was done to create a lever arm around the central axis. The lever arm is the perpendicular distance from the axis of rotation to the line of action of the force. The torque can be calculated by multiplying the length of the lever arm with the applied force. An increase in the length of the lever arm will decrease the force applied. This technique is cost-effective, simple, and applicable to all implant systems and can be effectively incorporated into those clinical situations in which the broken screws are not retrievable by conventional techniques. Further studies are required to assess the benefits of this technique over conventional methods of screw removal.

CONCLUSION

Abutment screw loosening is a recognized complication of implant placement. Adequate treatment planning, knowledge of the occlusal scheme, tightening to the correct torque, and regular recall appointments will minimize the incidence of abutment screw loosening and fracture. Removing a broken screw from an implant can be difficult.

There is no method of screw removal that can be universally applied. In this particular case, the screw was successfully removed using the prescribed technique. Therefore, this new technique may be used when removing a broken screw from the implant.

References

1. Jokstad A, Braegger U, Brunski JB, Carr AB, Naert I, Wennerberg A. Quality of dental implants. *Int Dent J*. 2003; 53: 409-443.
2. Satterthwaite J, Rickman L. Retrieval of a fractured abutment screw thread from an implant: a case report. *Br Dent J*. 2008; 204:177-180.
3. Balshi TJ. An analysis and management of fractured implants: a clinical report. *Int J Oral Maxillofac Implants*. 1996; 11:660-666.
4. Nergiz I, Schmage P, Shahin R. Removal of a fractured implant abutment screw: a clinical report. *J Prosthet Dent*. 2004; 91: 513-517.
5. Zarb GA, Schmitt A. The longitudinal clinical effectiveness of osseointegrated dental implants: the Toronto study. Part III: problems and complications encountered. *J Prosthet Dent*. 1990; 64: 185-194.
6. Kreissl ME, Gerds T, Muche R, Heydecke G, Strub JR. Technical complications of implant-supported fixed partial dentures in partially edentulous cases after an average observation period of 5 years. *Clin Oral Implants Res*. 2007; 18:720-726.
7. Haas R, Mensdorff-Pouilly N, Mailath G, Watzek G. Brane Branemark single tooth implants: a preliminary report of 76 implants. *J Prosthet Dent*. 1995; 73:274-279.
8. Green NT, Machtei EE, Horwitz J, Peled M. Fracture of dental implants: literature review and report of a case. *ImplantDent*. 2002; 11:137-143.
9. Eckert SE, Meraw SJ, Cal E, Ow RK. Analysis of incidence and associated factors with fractured implants: a retrospective study. *Int J Oral Maxillofac Implants*. 2000; 15:662-667.
10. Brunski JB, Puleo DA, Nanci A. Biomaterials and biomechanics of oral and maxillofacial implants: current status and future developments. *Int J Oral Maxillofac Implants*. 2000; 15:15-46.
11. Mericske SR, Assal P, Mericske E, Burgin W. Occlusal force and oral tactile sensibility measured in partially edentulous patients with ITI implants. *Int J Oral Maxillofac Implants*. 1995; 10:345-354.
12. Mollersten L, Lockowandt P, Linden LA. Comparison of strength and failure mode of seven implant systems: an in vitro test. *J Prosthet Dent*. 1997; 78:582-591.
13. Sanchez-Perez A, Moya-Villaescusa MJ, Jornet-Garcia A, Gomez S. Etiology, risk factors and management of implant fractures. *Med Oral Patol Oral Cir Bucal*. 2010; 15:504-508.
14. Maalhagh-Fard A, Jacobs LC. Retrieval of a stripped abutment screw: a clinical report. *J Prosthet Dent*. 2010; 104:212-215.750 Vol.
